

THE SMIL RADIOLOGY REPORT

IMAGING UPDATES YOU NEED TO KNOW • ESMIL.COM

Winter 2014

Cerebrovascular Disease: Achieving Clarity

Newer techniques prove useful for neuroimaging of aging patients



William Jones, MD

Computed tomographic (CT) and magnetic resonance imaging (MRI) techniques have been used in recent years to evaluate cerebrovascular disease and to document

structural abnormalities and functional impairments that occur in the brain and cerebral vasculature of aging patients.

In a review of techniques for neuroimaging of cerebrovascular disease, researchers at Weill Cornell Medical College identified several newer techniques that provide physicians greater clarity in the workup of these diseases in aging patients. These include higher resolution CT angiography (CTA) and MR angiography (MRA), as well as perfusion and diffusion tensor imaging techniques.

ON THE CUTTING EDGE

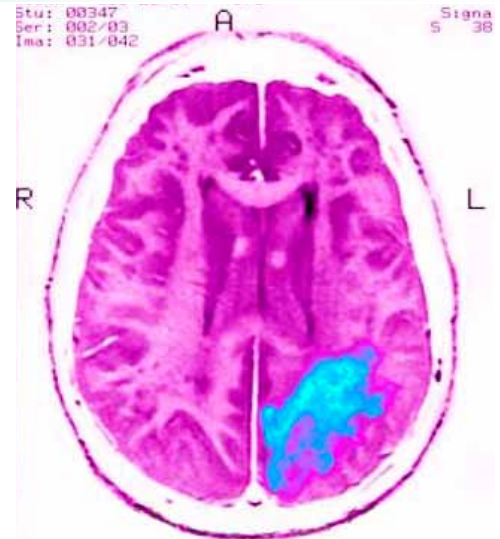
At Scottsdale Medical Imaging (SMIL), radiologists regularly employ angiographic studies, CTA or MRA, which look specifically at the vessels themselves,

when it comes to cerebrovascular disease, says William Jones, MD, a neuroradiologist at SMIL.

MRA doesn't require contrast, which can be an advantage, but patients must remain motionless. The SMIL advantage, Jones says, is that 3-Tesla MRA produces extremely high resolution for diagnosing cerebral ischemia and other brain disorders.

"We have a number of 3-Tesla magnets in our system, and MRAs, in particular, are much better at 3T versus a much smaller field strength like the 1.5 T," Jones says. "When there is some question, we can send patients to the 3-Tesla magnet and get a higher resolution study looking for very small aneurysms or small vascular irregularity."

In addition, with MR, SMIL radiologists use diffusion-weighted imaging on every case. Diffusion tensor imaging (DTI) is another MR technique that allows direct in vivo examination of the tissue microstructure; however, Jones says, it is generally reserved for academic studies mapping the location, orientation and directionally dependent properties (anisotropy) of the brain's white matter tracts for studies of white matter disorders.



Magnetic resonance image (MRI) of cerebrovascular disease, evidenced by a clot on the left hemisphere of the brain. SCIENCE SOURCE

If MRA is not possible, CTA is used, which requires contrast and radiation. However, SMIL uses a low-dose protocol to minimize the exposure.

"With contrast, you can see if one part of the brain is being poorly perfused compared to another part of the brain, which is very helpful in determining the next phase of treatment," Jones says. "We are always looking at new areas of imaging to improve and incorporate into our practice to improve detection and subsequent treatment." •

REFERENCE:

Gupta A, Nair S, Schweitzer A, et al. Neuroimaging of Cerebrovascular Disease in the Aging Brain. *Aging and Disease*. 2012;3(5):414-425.

INSIDE: 02
 New imaging guidelines for chronic rhinosinusitis

03
 New stroke/TIA protocol includes diffusion-weighted MRI of the brain

04
 A new weapon in the fight against prostate cancer

FREE
 Digital Subscription to *Phoenix Magazine*

Visit esmil.com/connect to renew your subscription to this publication and receive a free digital subscription to *Phoenix Magazine*.

New Recommendations for Chronic Rhinosinusitis

Imaging guidelines downgrade X-ray use



Sunil Ram, MD

In 2012, the Agency for Healthcare Research and Quality recommended downgrading X-ray imaging to “usually not appropriate” for sinonasal disease and acute and chronic sinusitis.

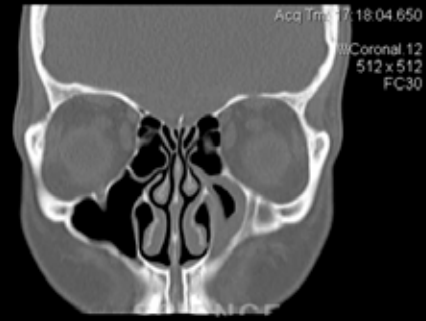
“Studies have shown that X-ray for acute sinusitis is not helpful and unnecessarily exposes the patient to radiation,” says Sunil Ram, MD, a neuroradiologist at Scottsdale Medical Imaging (SMIL). “A patient should only be imaged in the setting of chronic sinusitis in order to confirm the diagnosis, evaluate for anatomic

derangements and assist in potential surgical planning.”

Ram adds that SMIL encourages utilization of the American College of Radiology appropriateness criteria for sinonasal disease outlined in 2013. The ACR recommends CT as the imaging method of choice for the paranasal sinuses and states that coronal CT imaging gives the best overall anatomic detail.

“SMIL’s approach to head and neck imaging includes having all studies exclusively read by board-certified neuroradiologists,” Ram says. “Our introduction of low-dose techniques has reduced radiation exposure by up to 70 percent, without negatively affecting diagnostic image quality or assessment of anatomical structures.”

In those cases where anatomic variation



The American College of Radiology states that coronal CT offers the best overall anatomic detail of the paranasal sinuses.

LIVING ART ENTERPRISES, LLC / SCIENCE SOURCE

is suspected, imaging for diagnosis and surgical planning becomes essential, Ram says.

“We will often find anatomic variations that expose patients to chronic sinusitis. Many of these patients will be successfully treated with functional endoscopic sinus surgery,” he says. •

REFERENCE:

Agency for Healthcare Research and Quality, National Guideline Clearinghouse. ACR appropriateness criteria sinonasal disease.

Cornelius Rebecca, Martin Jamie, Wippold Franz, et al. ACR appropriateness criteria sinonasal disease. *Journal of the American College of Radiology*. 2013;10(4):241-246.

Essential Tremor Versus Parkinsonian Syndromes

DaTscan affects the diagnosis and management of movement disorders



Eric Kovalsky, MD

Differentiating between essential tremor (ET) and Parkinsonian syndromes (PS) became clearer with FDA approval of DaTscan, an imaging agent used with single photon emission computed tomography (SPECT), in 2011. The agent binds to the dopamine transporters (DaT) in the brain, which can be visualized by SPECT/CT. DaT concentrations are lower in patients with Parkinson’s disease but will generally be normal in those with ET.

In a study of 273 people with clinically

uncertain Parkinsonian syndromes, 50 percent of those in the DaTscan group had at least one change in clinical management by 12 weeks compared with 31 percent of those in the non-imaged group. In addition, the confidence in diagnosis score rose significantly more among the DaTscan group compared to the control group.

That degree of confidence has made DaTscans popular among neurologists. Eric Kovalsky, MD, a nuclear medicine radiologist at Scottsdale Medical Imaging (SMIL), says that SMIL radiologists already have extensive experience in DaTscan interpretation and currently perform multiple DaTscans in any given week.

“Neurologists find it helpful in confirming diagnosis,” Kovalsky says. “The goal

is to direct management of the patients. In those cases when a patient has already received a diagnosis and is responding well to treatment, then DaT/SPECT imaging would not add any new information and is unnecessary. It is the cases where the patient isn’t responding to treatment or where an invasive procedure is being considered that DaTscan can be very helpful. Clear and timely diagnosis paves the way for early intervention and disease management.”

SMIL has five physicians specially trained in nuclear medicine who are familiar with reading DaTscans and have been reading them since FDA approval, Kovalsky adds. •

REFERENCE:

Kupsch A, Bajaj N, Weiland F, et al. Impact of DaTscan SPECT imaging on clinical management, diagnosis, confidence of diagnosis, quality of life, health resource use and safety in patients with clinically uncertain parkinsonian syndromes: a prospective 1-year follow-up of an open-label controlled study. *J Neurol Neurosurg Psychiatry*. 2012;83:620-628

Imaging Options for Acute Stroke and TIA Patients

Unraveling the complexity of evaluation techniques



Steven Wise, MD

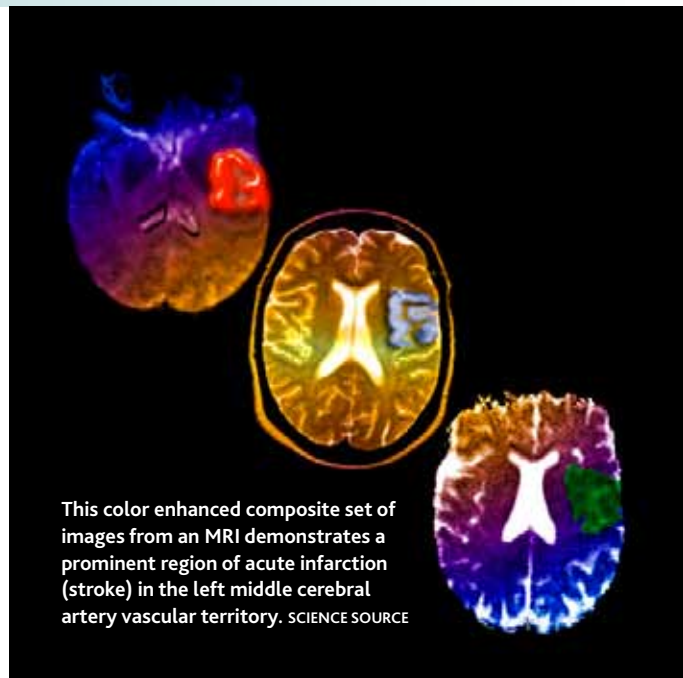
A wide variety of imaging techniques has become available to assess vascular lesions and brain tissue status in acute stroke patients. As a result of the multiple facets of these imaging techniques and complex algorithms, evaluation of patients for acute stroke or transient ischemic attack (TIA) is more complex than ever.

While the complexity of techniques is new, Steven Wise, MD, a neuroradiologist at Scottsdale Medical Imaging (SMIL), says that in the emergency setting some things remain the same.

“If the patient is within the zero- to six-hour window of an acute stroke, we want to make sure they are sent to the emergency department, not to the outpatient SMIL facility,” Wise says. “A noncontrast CT of the head should be obtained to determine eligibility for IV tPA or emergent neuroendovascular intervention, which could prevent a major stroke.”

Outside that six-hour window, or when initial stroke evaluation is inconclusive, Wise says that further workup of patients with neurologic deficits may benefit from MRI brain and MR angiography (MRA) of the head and neck.

“We’re introducing a new stroke/TIA protocol that includes MRI brain with diffusion weighted imaging and MRA of the head and neck, all without contrast,” Wise says. “One reason is that MRI brain is far more sensitive for detecting small infarcts than CTA and CT perfusion. Some of the elderly members of our community will often have these smaller infarcts, which will likely not be detected on other techniques.”



For MRA of the head, Wise says, SMIL radiologists will evaluate for a flow-limiting stenosis or an occluded major vessel. For the neck, they look for carotid and vertebral artery disease. In patients with neck pain, they might add a dissection protocol to the MRA of the neck, especially if it is a young patient having a stroke.

MRA neck can be performed with or without IV contrast if the proximal great vessels need to be evaluated, such as in patients with subclavian steal or vertebrobasilar symptoms.

CTA of the head and neck, either without or with CT perfusion with IV contrast is the imaging workup of choice in patients who are not eligible for MRI. •

REFERENCE:

Wintermark M, Sanelli P, Albers G, et al. Imaging recommendations for acute stroke and transient ischemic attack patients: a joint statement by the American Society of Neuroradiology, the American College of Radiology, and the Society of NeuroInterventional Surgery. *AJNR Am J Neuroradiol.* 2013;34:E117–E27.

“MRI brain is far more sensitive for detecting small infarcts than CTA and CT perfusion. Some of the elderly members of our community will often have these smaller infarcts, which will likely not be detected on other techniques,” says *Steven Wise, MD.*



Breast MRI Needed for High-Risk Patients

A pair of studies published online in *JAMA Internal Medicine* show that while more women at high risk for breast cancer are getting the recommended MRI breast screening, many more are not.



Denise Hartoin Reddy, MD

Denise Hartoin Reddy, MD, breast and women's imaging specialist at Scottsdale Medical Imaging (SMIL), says SMIL has been working with providers in the community to improve the appropriate use of breast MRI screening. "We continue to take important steps toward a program of more targeted screening for our community that will ensure all women get the breast cancer screening that is right for their risk level." *Continues online* ▶

ALSO ON THE NEW ESMIL.COM

You Can:

- Access PACS
- Submit an imaging order form
- Download the referring physician protocol guide
- Learn how to get involved in clinical research studies
- Contact your representative

Your Patients Can:

- Read more about the exam they are scheduled for
- Request a mammogram appointment
- Find the most convenient SMIL location
- Take advantage of online bill pay



Evaluating Dizzy Patients

While the majority of dizziness and vertigo are due to benign causes, a small number are due to serious conditions. This often leads to extensive neuroimaging and neurological workups.



Michelle Lai Dubes, MD

Michelle Lai Dubes, MD, a neuroradiologist at Scottsdale Medical Imaging (SMIL), says that once stroke, hemorrhage and space occupying mass are ruled out by non-contrast CT in the emergency department, it is often up to the primary care physician to follow up with the patient. Based on the referring physician's assessment, SMIL's neuroradiologists can help decide the proper course of imaging study or studies to be performed. *Continues online* ▶

Neuroimaging in Ophthalmology



Sunil Ram, MD

In a review of common neuro-ophthalmic disorders, researchers recommend MRI with contrast for unilateral or bilateral optic neuropathy, optic neuritis, bitemporal hemianopsia and several others.

Sunil Ram, MD, a neuroradiologist at Scottsdale Medical Imaging (SMIL), says SMIL's emphasis on service ensures that referring physicians obtain the appropriate imaging study required for a confident diagnosis. *Continues online* ▶

A New Weapon in the Fight Against Prostate Cancer

The current state of prostate cancer diagnosis by transrectal ultrasound (TRUS) guided sextant biopsy is generally reliable. However, some cancers can be missed, and the rate of false negatives can be high when a cancer is present elsewhere in the prostate. The combination of two technologies will bring prostate cancer diagnosis closer to that of breast cancer diagnosis, says Raymond Murphy, MD, PhD, a radiologist at Scottsdale Medical Imaging.



Raymond Murphy, MD, PhD

Using multi-parametric MRI (MPMRI) combined with new office-based MRI-ultrasound equipment, urologists will be able to directly biopsy lesions to examine for cancer, Murphy says. *Continues online* ▶



Read the full articles at esmil.com/connect.